

## Spontaneous Resolution of an Indirect (Dural) Carotid Cavernous Fistula Following Pregnancy: A Case Report

Sekarlia Wiarsi Fristiari<sup>1</sup>, Delfitri Lutfi<sup>1,2\*</sup>, Nur Setiawan Suroto<sup>3</sup>

<sup>1</sup>Department of Ophthalmology, Faculty of Medicine Universitas Airangga, Surabaya, Indonesia

<sup>1,2\*</sup>Department of Ophthalmology, Dr. Soetomo General Academic Hospital, Surabaya, Indonesia

<sup>3</sup>Department of Neurosurgery, Dr. Soetomo General Academic Hospital, Surabaya, Indonesia

**Corresponding Author:** Delfitri Lutfi, Department of Ophthalmology, Dr. Soetomo General Academic Hospital, Surabaya, Indonesia Jl. Prof. DR. Moestopo No.6-8, Airlangga, Kec. Gubeng, Surabaya, Jawa Timur 60286, delfitri-l@fk.unair.ac.id and (031)5020251.

Received: 11th Sept, 2025

Accepted: 31st Oct, 2025

Published: 16th Dec, 2025

### ABSTRACT

**Introduction:** Indirect (dural) carotid–cavernous fistula (CCF) is the most common dural arteriovenous communication. Pregnancy is a recognized precipitating factor, as hormonal and hemodynamic changes in late pregnancy or at delivery can trigger fistula formation. However, the occurrence of CCF after delivery is rare, with only a few cases reported in the literature.

**Case Presentation:** 25-year-old woman developed left eye redness, pain, proptosis, tearing, and progressive visual blurring starting one week postpartum after a pre-eclamptic cesarean delivery at 33–34 weeks. Examination revealed left eye visual acuity 6/20, elevated intraocular pressure, eyelid edema, conjunctival hyperemia, chemosis, and tortuous “corkscrew” vessels. Fundus examination showed disc hyperemia and retinal vein dilation. No ocular bruit was detected. Imaging with CT angiography demonstrated a left internal carotid artery–cavernous sinus shunt.

**Discussion:** Indirect CCF may mimic orbital inflammatory disorders, making early recognition challenging. Digital subtraction angiography (DSA) remains the gold standard for diagnosis. Management depends on flow and symptom severity: low-flow dural fistulas may resolve spontaneously or with manual carotid compression, whereas high-flow or symptomatic fistulas typically require endovascular embolization with neurosurgeon.

**Conclusion:** Pregnancy-related hormonal and hemodynamic changes can precipitate indirect dural CCF. While embolization is the mainstay of therapy, low-flow fistulas may close conservatively. Early detection, prompt imaging, and multidisciplinary follow-up are essential to preserve vision and optimize outcomes.

**KEYWORDS:** Dural arteriovenous fistula, indirect carotid–cavernous fistula, postpartum ophthalmopathy, vascular disorder.

**How to Cite:** Sekarlia Wiarsi Fristiari, Delfitri Lutfi, Nur Setiawan Suroto, (2025) Spontaneous Resolution of an Indirect (Dural) Carotid Cavernous Fistula Following Pregnancy: A Case Report, *Vascular and Endovascular Review*, Vol.8, No.5s, 284-289.

### INTRODUCTION

Orbital inflammation is a frequent condition affecting both adults and children, representing most orbital pathologies. The clinical presentation may be acute, subacute, or insidious, reflecting the wide spectrum of underlying causes. Conceptually, orbital inflammatory diseases can be classified as either specific, when an identifiable cause is present, or nonspecific, when no clear etiology is found.<sup>1</sup> Among conditions that may mimic orbital inflammation is the carotid–cavernous sinus fistula (CCF),<sup>2</sup> an abnormal communication between the carotid arteries and the cavernous sinus. The resulting venous congestion often produces orbital signs, which can be unilateral or bilateral, including orbital discomfort, pulsatile proptosis, conjunctival chemosis, periorbital edema, and ophthalmoplegia.<sup>3</sup>

CCF can be further classified anatomically as either direct or indirect. Direct CCF involves a direct communication between the cavernous segment of the internal carotid artery and the cavernous sinus, whereas indirect (dural) CCF arises from abnormal connections between the cavernous sinus and dural branches of the carotid artery.<sup>4</sup> Etiologically, CCF can be traumatic, typically resulting from penetrating head injuries or major skull fractures, or spontaneous.<sup>5</sup> Spontaneous lesions may arise from congenital arteriovenous malformations, or be associated with systemic conditions such as atherosclerosis, hypertension,<sup>6</sup> connective tissue disorders (e.g., Ehlers-Danlos syndrome),<sup>7</sup> pregnancy, childbirth, or the puerperium.<sup>8</sup>

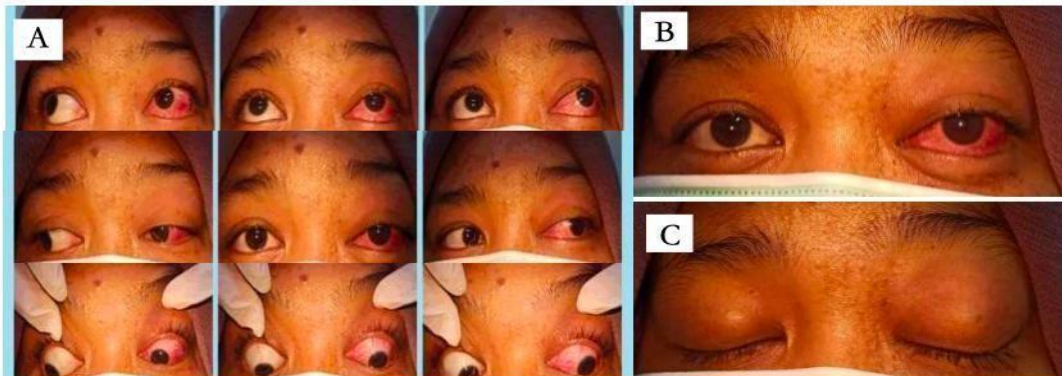
Although rare, spontaneous CCF during pregnancy has been well documented and is considered a potential trigger.<sup>9–14</sup> Studies suggest that 20–30% of spontaneous CCFs in this context develop during the second half of pregnancy or around childbirth. The precise mechanism remains unclear, but it is hypothesized that pregnancy-related hemodynamic changes, including elevated blood pressure, may precipitate rupture of pre-existing cavernous sinus aneurysms.<sup>8</sup> CCF should be suspected in patients

presenting with mild proptosis, conjunctival chemosis, or dilated episcleral vessels, particularly when orbital bruits are detected,<sup>15</sup> and confirmed through digital subtraction angiography (DSA).<sup>8</sup> In our patient, orbital inflammation corresponded to an indirect CCF occurring after pregnancy, which subsequently resolved spontaneously.

## CASE PRESENTATION

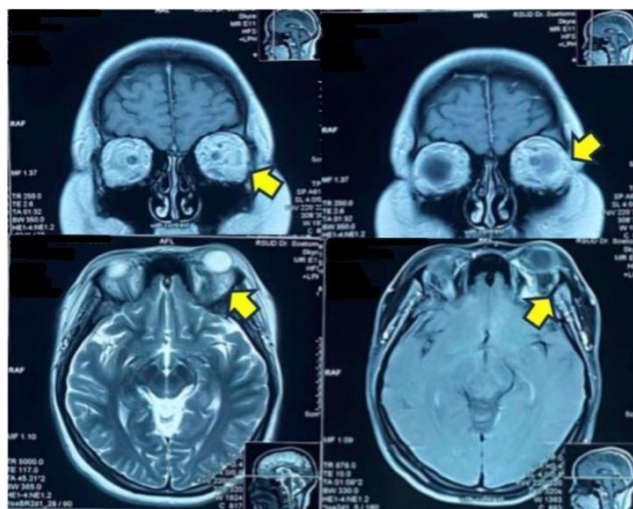
A 25-year-old woman presented with redness and pain in her left eye that had persisted for a month, beginning one week postpartum. Over the past two weeks, she experienced progressively blurred vision, tearing, and gradual proptosis. She had been treated with timolol eye drops twice daily and oral methylprednisolone every eight hours for two weeks without improvement. Her medical history was notable for pre-eclampsia during pregnancy, with delivery via cesarean section at 33–34 weeks of gestation one month prior. She denied chest palpitations, recurrent red eye, eyelid masses, diabetes, hypertension, asthma, or thyroid disease. There was no family history of similar ocular conditions or prior use of spectacles.

On examination, visual acuity was 6/6 in the right eye and 6/20 (PH 6/12) in the left eye. Intraocular pressure measured 18 mmHg in the right eye and 34 mmHg in the left. Extraocular movements of the left eye were limited in the superomedial, medial, and inferomedial directions without pain.



**Figure 1. A Ocular motility. B was front view when the patient opened her eyes. C. was front view when the patient closed eye. \*Pictures were taken with patient's consent, Courtesy: RSUD Dr Soetomo**

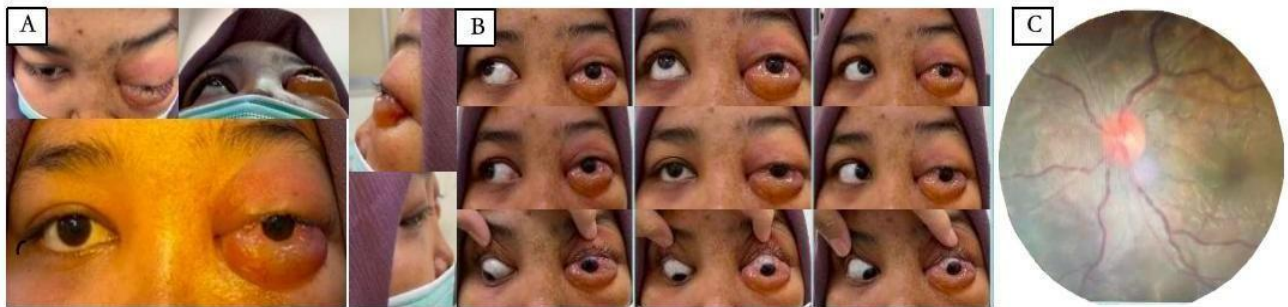Anterior segment examination revealed proptosis, eyelid swelling, conjunctival hyperemia, episcleral vessel dilation, chemosis, and temporal corkscrew vessels in the left eye, while the right eye was normal (**Figure 1**). No orbital bruit was detected. Posterior segment examination showed a normal right eye, whereas the left eye exhibited tortuous vessels.



**Figure 2. An MRI showed no residual masses at the surgical site. There were no infarctions, hemorrhages, masses, or infectious processes in the brain parenchyma**

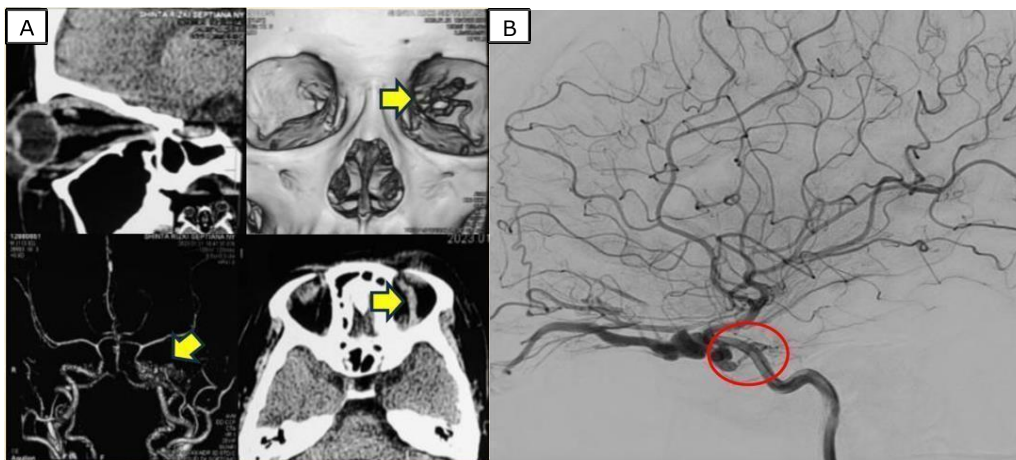
Magnetic resonance imaging (MRI) revealed no residual masses at the surgical site and no infarctions, hemorrhages, masses, or infectious processes in the brain parenchyma (**Figure 2**). The initial working diagnosis was left orbital cellulitis, with differential considerations including nonspecific orbital inflammation (NSOI) and suspected CCF with secondary glaucoma. Treatment comprised intravenous ceftriaxone and metronidazole, oral paracetamol, and topical levofloxacin, cenfresh, timolol, and glaupac.

Eleven days later, she returned with worsening blurred vision, pain, redness, proptosis, chemosis, and corkscrew conjunctival vessels (**Figure 3**). Fundoscopic examination of the left eye revealed a well-defined optic disc with peripapillary atrophy, disc hyperemia, and retinal vein dilation, while the right eye remained normal.



**Figure 3:** A. Segment anterior. B. Ocular motility, the patient showed a fixed eye C. was left eye showed a defined border optic disc with peripapillary atrophy, disc hyperemia, retinal vein dilatation, and no intra-retinal hemorrhage \*Pictures were taken with patient's consent, Courtesy: RSUD Dr Soetomo

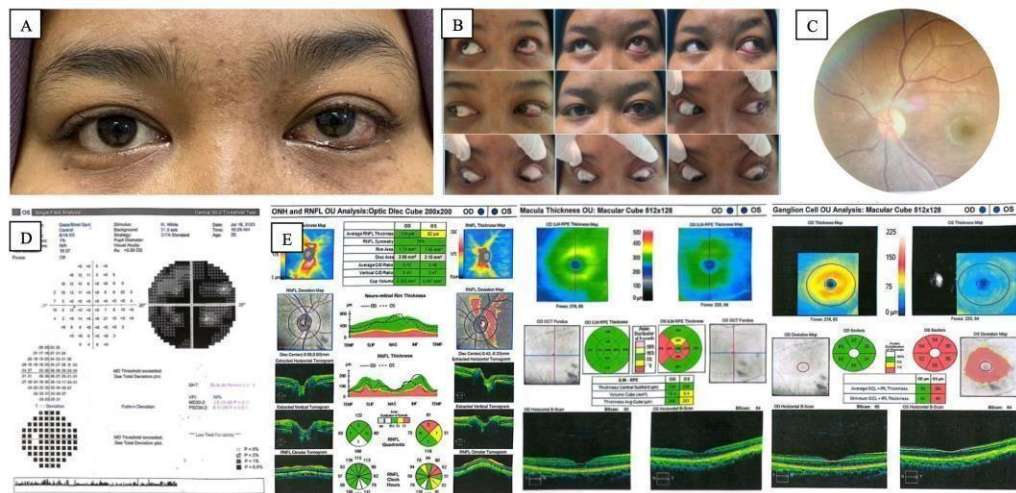
Computed Tomography (CT) Angiography revealed dilatation and kinking of the superior ophthalmic vein (largest diameter  $\sim 3.3$  mm) and a shunt between the left internal carotid artery and the left cavernous sinus, with a fistula diameter of  $\sim 3.1$  mm. Left eye proptosis was also noted. These findings were consistent with a type A direct carotid-cavernous fistula according to Barrow's classification. No infarctions, hemorrhages, or infectious processes were identified in the brain parenchyma (**Figure 4A**). The patient was referred to neurosurgery for DSA and embolization (**Figure 4B**).



**Figure 4 :** A. Computed Tomography (CT) Angiography revealed there was dilatation and kinking of the superior ophthalmic vein with the largest diameter of  $\pm 3.3$  mm. There were shunting between the left internal carotid artery (left ICA) and the left sinus cavernous with a fistula diameter of  $\pm 3.1$  mm. Proptosis of the left bulbus oculi. B. Digital subtraction angiography examination (DSA) revealed there was a fistula in the meningeal branch of the internal carotid artery (ICA) with the cavernous sinus.

Subsequently, the patient was diagnosed with a left eye cavernous dural arteriovenous fistula (indirect CCF, type B). She was instructed to perform manual external carotid compression for 15 minutes every 12 hours while seated, using the contralateral hand. Routine outpatient follow-up was conducted at Dr. Soetomo Hospital.

Three months later, the patient returned with blurred vision in the left eye. Visual acuity was 6/6 in the right eye and 1/60 in the left. Intraocular pressures were 14 mmHg and 13 mmHg in the right and left eyes, respectively. The right eye remained normal, whereas the left eye showed mild conjunctival injection, hyperemia, minimal chemosis, and minimal corkscrew vessels temporally (**Figure 5A**). Extraocular movements were full and painless in both eyes. Pupils were 3 mm, round, regular, and reactive to light bilaterally (**Figure 5B**). Ocular bruit was absent in the left eye. Fundoscopic examination of the left eye revealed a pale optic disc with regular borders, without elevation, Paton lines, or vessel obscurations (**Figure 5C**).



**Figure 5: A Segment anterior. B Ocular motility, both eyes were within normal limits C. Funduscopy examination D. Humphrey Perimetry E. Optical Coherence Tomography (OCT) \*Pictures were taken with patient’s consent, Courtesy: RSUD Dr Soetomo**

Visual field examination with Humphrey perimetry showed within normal limits in the right eye and general depression in the left eye (Figure 5D). Optical Coherence Tomography (OCT) in the left eye revealed thinning of the Retinal Nerve Fiber Layer (RNFL) in the superior and temporal quadrants, thinning of Inner Limiting Membrane-Retinal Pigment Epithelium (ILM-RPE) in the nasal and inferior quadrants, and also thinning of Ganglion Cell-Inner Plexiform Layer (GCL- IPL) in all quadrants (Figure 5E).

Treatment included oral RG choline (2×1 tablet daily) and folic acid (1×1 tablet daily). The patient’s prognosis was considered *quo ad vitam: dubia ad bonam, quo ad functionam: dubia malam, and quo ad sanationam: dubia malam*.

**DISCUSSION**

Pregnancy-related hormonal and hemodynamic changes can precipitate the development of indirect (dural) carotid–cavernous fistulas (CCFs).<sup>8</sup> Increased blood volume and vascular flow may enhance arteriovenous shunting, contributing to fistula formation. Although spontaneous dural CCFs can resolve in 6–43% of cases,<sup>16</sup> postpartum improvement is rare. Our patient’s presentation with subtle conjunctival hyperemia, corkscrew vessels, proptosis, elevated intraocular pressure, ophthalmoplegia, disc hyperemia, and retinal vein dilation, illustrates the insidious onset typical of low-flow, indirect fistulas.

The cavernous sinus (CS) is a dural venous confluence connecting orbital, cranial, and posterior fossa venous systems.<sup>17</sup> Cranial nerves III, IV, VI, V1, V2, and VI traverse the CS,<sup>18</sup> making them susceptible to compression and ischemic injury in CCFs,<sup>19,20</sup> as evidenced by our patient’s ophthalmoplegia. Imaging is essential for diagnosis, such as CT and MRI<sup>21</sup> that show superior orbital vein dilation and extraocular muscle enlargement, while orbital Doppler can detect abnormal flow.<sup>5</sup> Digital subtraction angiography (DSA) remains the gold standard,<sup>8,22</sup> particularly for subtle dural fistulas. In this patient, CT angiography revealed a left ICA-CS shunt, consistent with Barrow type A direct fistula.

CCFs can be classified by etiology (traumatic vs. spontaneous), hemodynamics (high vs. low flow), and angioarchitecture (direct vs. indirect).<sup>3,21,23</sup> According to Barrow’s classification, type A refers to direct ICA–CS fistulas (high-flow, usually traumatic), whereas types B–D are indirect fistulas involving meningeal branches of the ICA, ECA, or both.<sup>15,24</sup> Traumatic CCFs constitute 70–75% of cases,<sup>25</sup> predominantly in young males,<sup>26</sup> while spontaneous CCFs account for 25–30%, most commonly affecting older females<sup>22</sup> or postpartum women. Pregnancy has been suggested as a trigger for spontaneous dural CCF, though only six cases have been reported in the literature (Table 1).<sup>9–14</sup>

**Table 1. Characteristics of reported cases of pregnancy-associated spontaneous dural CCF.**

Authors	Age (years)	Onset during pregnancy	Symptoms	Location	Intervention	Clinical course
Doyon and Metzger <sup>9</sup>	N/A	N/A	N/A	Cavernous sinus	N/A	N/A
Toya et al. <sup>13</sup>	21	6th week	Chemosis, diplopia, exophthalmos	Cavernous sinus	Abortion	Spontaneous improvement after abortion
	25	28th week	Pulsatile tinnitus	Cavernous sinus	None	Spontaneous improvement after catheter angiography
Lasjaunias et al. <sup>14</sup>	N/A	N/A	N/A	Cavernous sinus	N/A	N/A

Hirata et al. <sup>11</sup>	32	2nd month	Chemosis, exophthalmos	Cavernous sinus	None	Spontaneous improvement after delivery
Yeung et al. <sup>12</sup>	41	30th week	Headache, chemosis, diplopia, pulsatile tinnitus	Cavernous sinus	Transvenous embolization after delivery	N/A
Ishigami et al. <sup>10</sup>	28	23rd week	Pulsatile tinnitus	Cavernous sinus	Transarterial embolization	Marked improvement after intervention

Management depends on flow characteristics and symptom severity.<sup>15</sup> High-flow direct fistulas require urgent intervention, while low-flow indirect fistulas may respond to conservative approaches, including manual carotid compression or endovascular embolization.<sup>27</sup> Embolization is preferred, achieving closure in over 90% of cases,<sup>28</sup> though complications such as thrombosis, cranial neuropathy, or recanalization may occur.<sup>29</sup> In this patient, embolization via the superior ophthalmic vein was technically limited, thus manual carotid compression resulted in symptomatic improvement, though visual acuity remained impaired.

Complications of CCF include hemorrhage,<sup>30</sup> elevated intracranial pressure, and vision loss.<sup>22</sup> Ocular signs often resolve immediately after fistula closure, whereas proptosis, chemosis, venous congestion, and disc swelling may take weeks to normalize. Persistent optic nerve dysfunction, as observed here, highlights the importance of early diagnosis and individualized management. Differential diagnoses include orbital cellulitis, nonspecific orbital inflammation, thyroid eye disease, retrobulbar hemorrhage, lacrimal gland tumors, cavernous sinus thrombosis, and vascular malformations.

## CONCLUSION

Pregnancy-related hormonal and hemodynamic changes may precipitate indirect dural carotid–cavernous fistulas. Low-flow fistulas can resolve spontaneously or with conservative measures, such as manual carotid compression, but visual impairment may persist despite symptomatic improvement. Early recognition, timely imaging, and multidisciplinary management are critical to preserve vision.

## ACKNOWLEDGMENTS

### Ethics approval and consent to participate

The patient provided written informed consent for participation and publication of this case report.

### Consent for publication

Not applicable.

### Competing interests

The authors declare no conflict of interest.

### Funding

This research received no external funding.

## REFERENCES

- Korn BS. Oculofacial Plastic and Orbital Surgery. vol. Section 7. San Francisco: American Academy of Ophthalmology; 2022.
- Lacorzana J, Rocha-de-Lossada C, Ortiz-Perez S. A tricky case of unilateral orbital inflammation: carotid cavernous fistula in Graves-Basedow disease. *Romanian J Ophthalmol* 2021;65:201–3. <https://doi.org/10.22336/rjo.2021.40>.
- Bhatti MT. Neuro-Ophthalmology. vol. Section 5. San Francisco: American Academy of Ophthalmology; 2022.
- Putri ND, Prasetyo BT, Kurniawan RG, et al. Carotid-Cavernous Fistula: Manifestasi Klinis dan Tatalaksana. *J Indones Med Assoc* 2023;73:102–7. <https://doi.org/10.47830/jinma-vol.73.2-2023-880>.
- Post-Traumatic Carotid-Cavernous Fistula: A Case Report. *J Med Case Rep Case Ser* 2024. <https://doi.org/10.38207/JMCRCS/2024/JAN05020316>.
- Pickel L, Micieli JA. The Development of Indirect Carotid Cavernous Fistulas after Microvascular Ischemic 4th Nerve Palsies. *Case Rep Ophthalmol* 2022;13:700–5. <https://doi.org/10.1159/000526566>.
- Kohli GS, Patel BC. Carotid Cavernous Fistula. *StatPearls*, Treasure Island (FL): StatPearls Publishing; 2025.
- Cobbs LV, Sheng Y, Amanullah SE, et al. CASE REPORTS: Carotid cavernous fistula masquerading as orbital inflammation on noninvasive imaging in a peripartum patient. *Digit J Ophthalmol* 2023. <https://doi.org/10.5693/djo.02.2022.11.001>.
- Doyon D, Metzger J. [Dural supratentorial vascular malformations of posterior fossa]. *Acta Radiol Diagn (Stockh)* 1972;13:792–800.
- Ishigami D, Koizumi S, Ishikawa O, et al. Embolization of dural arteriovenous fistula during twin pregnancy – A case report and literature review. *Interv Neuroradiol* 2021;27:658–62. <https://doi.org/10.1177/1591019921991396>.
- Hirata Y, Matsukado Y, Takeshima H, et al. Postpartum Regression of a Spontaneous Carotid-cavernous Fistula: — Case Report—. *Neurol Med Chir (Tokyo)* 1988;28:673–6. <https://doi.org/10.2176/nmc.28.673>.

12. Yeung S, Suen SS, Yu SC, et al. Spontaneous carotid cavernous fistula complicating pregnancy. *Hong Kong Med J* 2013;19:258–61. <https://doi.org/10.12809/hkmj133634>.
13. Toya S, Shiobara R, Izumi J, et al. Spontaneous carotid-cavernous fistula during pregnancy or in the postpartum stage: Report of two cases. *J Neurosurg* 1981;54:252–6. <https://doi.org/10.3171/jns.1981.54.2.0252>.
14. Lasjaunias P, Halimi P, Lopez-Ibor L, et al. [Endovascular treatment of pure spontaneous dural vascular malformations. Review of 23 cases studied and treated between May 1980 and October 1983]. *Neurochirurgie* 1984;30:207–23.
15. Miller NRA. Walsh and Hoyt's Clinical Neuro-Ophthalmology: the Essential. Fourth Edition. United States of America: Lippincott Williams & Wilkins; 2020.
16. Gonzalez Castro LN, Colorado RA, Botelho AA, et al. Carotid-Cavernous Fistula: A Rare but Treatable Cause of Rapidly Progressive Vision Loss. *Stroke* 2016;47. <https://doi.org/10.1161/STROKEAHA.116.013428>.
17. Tanoue S, Hirohata M, Takeuchi Y, et al. Venous Anatomy of the Cavernous Sinus and Relevant Veins. *J Neuroendovascular Ther* 2020;14:547–57. <https://doi.org/10.5797/jnet.ra.2020-0086>.
18. Morcos JJ, Sun MZ. Surgical Anatomy of the Cavernous Sinus and Refinement of Its Surgery. In: Kanaan IN, Beneš V, editors. *Neuroanat. Guid. Success. Neurosurg. Interv.*, Cham: Springer Nature Switzerland; 2024, p. 397–411. [https://doi.org/10.1007/978-3-031-59838-8\\_38](https://doi.org/10.1007/978-3-031-59838-8_38).
19. Painful Ophthalmoplegia in Carotid-Cavernous Fistula. *JPHV J Pain Vertigo Headache* 2022;3:1–5. <https://doi.org/10.21776/ub.jphv.2022.003.01.1>.
20. Gunna NT, Paritala A, Takkar B, et al. Ocular ischaemic syndrome following coil embolisation for direct carotid cavernous fistula. *BMJ Case Rep* 2021;14:e242121. <https://doi.org/10.1136/bcr-2021-242121>.
21. Krothapalli N, Fayad M, Sussman E, et al. Carotid cavernous fistula: A rare but treatable cause of ophthalmoplegia - A case report. *Brain Circ* 2023;9:30–4. [https://doi.org/10.4103/bc.bc\\_64\\_22](https://doi.org/10.4103/bc.bc_64_22).
22. Al-shalchy A, Al-Wassiti AS, Hashim MA, et al. Neuro-Ophthalmic Manifestations of Carotid Cavernous Fistulas: A Systematic Review and Meta-Analysis. *Cureus* 2024. <https://doi.org/10.7759/cureus.65821>.
23. Saleem MS, Yadlapalli SS, Jamil S, et al. Traumatic Carotid Cavernous Fistula Resulting in Symptoms in the Ipsilateral Eye: A Case Report. *Cureus* 2022. <https://doi.org/10.7759/cureus.30950>.
24. Barrow DL, Spector RH, Braun IF, et al. Classification and treatment of spontaneous carotid-cavernous sinus fistulas. *J Neurosurg* 1985;62:248–56. <https://doi.org/10.3171/jns.1985.62.2.0248>.
25. Salmon J. Kanski's Clinical Ophthalmology: A Systematic Approach. Tenth Edition. India: Elsevier; 2025.
26. Sadewo W, Nugroho SW, Tobing HG, et al. Characteristics of Patients with Carotid-Cavernous Fistula who Underwent Endovascular Intervention. *EJournal Kedokt Indones* 2024;12:132. <https://doi.org/10.23886/ejki.12.822.132>.
27. Zeineddine HA, Lopez-Rivera V, Conner CR, et al. Embolization of carotid-cavernous fistulas: A technical note on simultaneous balloon protection of the internal carotid artery. *J Clin Neurosci* 2020;78:389–92. <https://doi.org/10.1016/j.jocn.2020.04.015>.
28. Liang J, Xie X, Sun Y, et al. Bilateral carotid cavernous fistula after trauma: a case report and literature review. *Chin Neurosurg J* 2021;7:46. <https://doi.org/10.1186/s41016-021-00265-x>.
29. Liao W-J, Hsiao C-Y, Chen C-H, et al. Spontaneous Resolution of an Aggressive Direct Carotid Cavernous Fistula Following Partial Transvenous Embolization Treatment: A Case Report and Review of Literatures. *Medicina (Mex)* 2024;60:2011. <https://doi.org/10.3390/medicina60122011>.
30. Asad SD, Nigam M, Rhee JY, et al. Carotid-Cavernous Fistula: A Rare Cause of Cerebellar Hemorrhage. *Stroke* 2023;54. <https://doi.org/10.1161/STROKEAHA.122.040816>.